ENT.

ELECTIVE REPORT
April – May 2011
Jemma Batte

HO CHI MINH CITY
VIETNAM


ENT Hospital


Hung Vuong Hospital

On my first day at the ENT Hospital, I was warmly welcomed by Dr Dung, my contact through Vital Links for Humanity. My first morning was in theatre, where I observed two mastoidectomies. I was struck by the similarities, rather than the differences, between theatres in the UK and this one, in Vietnam. The equipment, from the operating table to the lights to the microscope and video screen, was almost identical to that in London. Likewise, the surgical procedure was the same. The main differences concerned the patient rather than the surgery: for example, patients walked into theatre to be anaesthetised on the operating table, which is rare in the UK; and they never wore TED stockings. Furthermore, there were no 'WHO checks' prior to starting any procedure - patients did not even wear identification wristbands (they had their names paper-clipped to their pyjama collars).

Figure 1. *A comparison of theatres in Vietnam and the UK*

Similarities	Differences
• Surgical procedure (including anaesthetic, scrubbing, draping, cleaning of patient, as well as the surgery and wound closure)	• Cotton drapes and scrubs in Vietnam, disposable in the UK
• Surgical equipment (including table, lights, microscope, video screen, surgical instruments)	• Patients walk into theatre to be aneasthetised on the table in Vietnam, but are anaesthetised in an adjacent anaesthetic room in the UK
• Staff present (including anaesthetist, surgeon +/- assistant, scrub nurse)	• Patients do not wear TED stockings in Vietnam, but do so in the UK
	• No patient ID wristbands in Vietnam, unlike in the UK
	• No WHO check before the procedure in Vietnam, unlike in the UK
	• There is no procedure for careful moving and handling of patients at the end of the procedure, to transfer the patient from table to bed at the end of the procedure in Vietnam

On various days, I observed several procedures, including mastoidectomies, FESS (Functional Endoscopic Sinus Surgery), septoplasties, polypectomies, tonsillectomies, adenoidectomies and manipulations of fractured noses under anaesthetic. The most interesting cases I saw were the incision and drainage of an uncommon parapharyngeal abscess and the resection of a frontal sinus osteoma.

I spent the bulk of my time in Endoscopy clinic, where nasal endoscopy, laryngoscopy and otoscopy were performed.

Figure 2 – *Nasal endoscopy clinic*

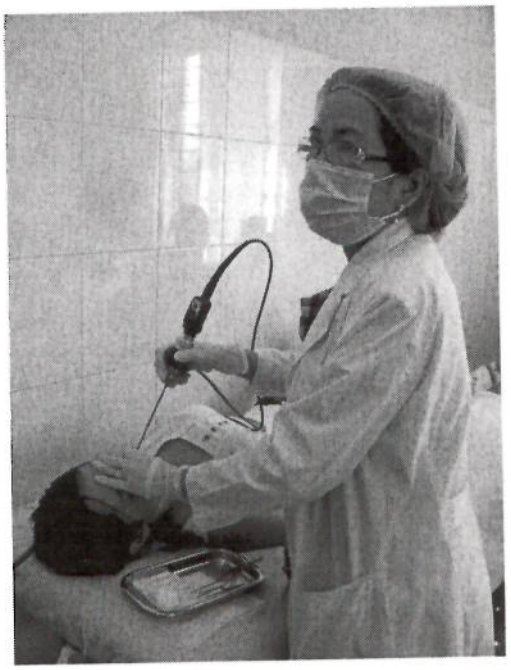

Figure 3. *Common presenting conditions in ENT Endoscopy Clinics*

Nasendoscopy	Otoscopy	Laryngoscopy
Sinusitis	Post-surgical follow-up	Benign vocal cord nodules
Headache	Otitis media with effusion (OME)	Inflammation of arytenoids (due to GORD)
Septal deviation/hook	Tympanic membrane perforation	Laryngeal polyps
Hypertrophy of inferior turbinate	Otitis externa	
Septal haemangiomas	Ear wax blockage of auditory canal	
Facial trauma/fractured nose	Polyps in external auditory canal	
Foreign body		
Rhinitis medicamentosa		

Unexpectedly, headaches were among the most common presenting conditions in nasal endoscopy clinic and the reason for this is discussed below (see Box.1).

Box 1 *Headache – an illustrative example of health provision in Vietnam*

There were many patients who attended Endoscopy clinics with headache. In Vietnam, a patient with a headache may seek treatment in a number of ways:

1. Attend the practice of their family doctor
2. Attend their District Hospital
3. Attend the relevant Specialist Hospital

There is no strict system of primary, secondary and tertiary care in Vietnam. Thus it is quite common for a patient to self-refer to the ENT hospital if, for example, they suspect a sinus problem as the cause of their headache. As a result, ENT doctors see a large number of patients with headaches unrelated anatomically to the ears, nose or throat. They will often order a skull x-ray and a CT head scan to satisfy the patient before prescribing simple analgesia. This tends to cause dissatisfaction among ENT doctors, as they are unable to utilise their specialist knowledge.

Furthermore, since family doctors are not commonly consulted, there is no single practitioner who keeps track of a patient's referrals, investigations and treatments, nor is there a centralised medical record. This, in my opinion, is the major disadvantage to the Vietnamese healthcare system: it makes history taking very difficult if a patient cannot remember exactly all their past diagnoses and treatments. The fact that different specialties are kept apart in different specialist hospitals also means that inter-specialty multidisciplinary care is almost unheard of. If I had more time on this elective, I would most like to see how oncological care is managed, to understand how the challenge of having surgeons, radiologists, oncologists and other specialists is met without their working in the same location.

I also attended the minor procedures rooms, run by specialist nurses for nasal washouts, ear irrigation, wax microsuction and removal of fish bones stuck in the oropharynx, and I spent a valuable day with a specialist nurse in the audiology department, observing her fitting newly molded in-ear hearing aids for children with hearing impairment and conducting hearing tests.

Figure 4 – *Fitting a new in-hear hearing aid for a child in the audiology department*

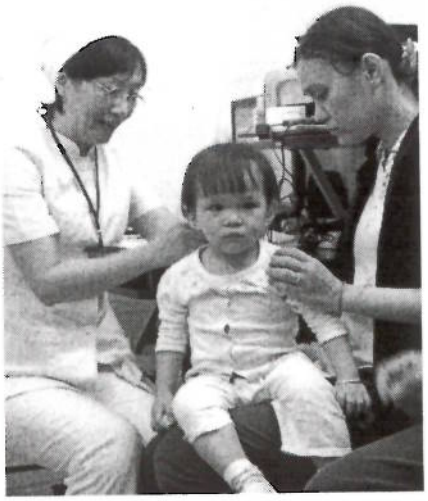

My next placement was at Hung Vuong Hospital, a large specialist Obstetrics & Gynaecology hospital. On my first day, it seeemd the doctors and midwives had high expectations of my skills in the delivery room - whilst they were very keen to offer me opportunities to assist in labour, I was at first only happy to observe as I lacked confidence in my abilities. The labour ward consisted of four bays - each containing 4-8 beds (not separated by curtains), weighing scales and a shared incubator - as well as a theatre for emergency C-sections. Within hours of arriving on my first day, I had seen the suturing of a grade II perineal tear, two natural births and a forceps-assisted delivery. An obstetrician then guided me through the management of the third stage of labour – the delivery of the placenta. Alas, this proved a little too much too fast in the heat and humidity and I nearly fainted!

Luckily, things improved as the days went on - whilst on the labour ward, I observed many more natural deliveries and C-sections and I sutured some perineal tears myself. However, I felt very uncomfortable with some of the midwifery practices I saw, including the percussion of a woman's abdomen to induce contractions and CPR-style compressions to speed delivery. I asked many questions about these seemingly brutal techniques (by which the labouring women were remarkably unfazed) and discovered that, whilst they are not supported by evidence in the literature, it is difficult to discourage their use amongst Vietnamese midwives as their practice is so widespread. Thus I learned an important lesson about the delay between evidence-based practice and existing techniques in a developing country such as Vietnam, which is much greater than in the UK.

There were also opportunities to attend the high risk pregnancy unit and family planning department and I discovered that Hung Vuong Hospital is incredibly busy, with scores of patients in the various waiting areas around the hospital. However, during the course of my placement, I realised that Obstetrics & Gynaecology is not, after all, the specialty for me, mainly due to my experiences on the labour ward.

Figure 5 – *Typical waiting areas in Hung Vuong Hospital*



In summary, my elective taught me that Obstetrics & Gynaecology is not the right career for me, but I learned valuable lessons about evidence-based medicine in a developing country. It strengthened my interest in ENT and I gained confidence in recognising common pathologies, as well as experience of common outpatient procedures. I am inspired to pursue ENT as my future career and I would like to thank Dr Dung, Dr Quang and Dr Anh for their kindness and expert guidance throughout my placements.